



A Case Report of Advanced Unruptured Cornual Pregnancy

Yitbarek F



Introduction

Cornual pregnancy is one of the rare form of ectopic pregnancy which carries the major risk of maternal morbidity and mortality.

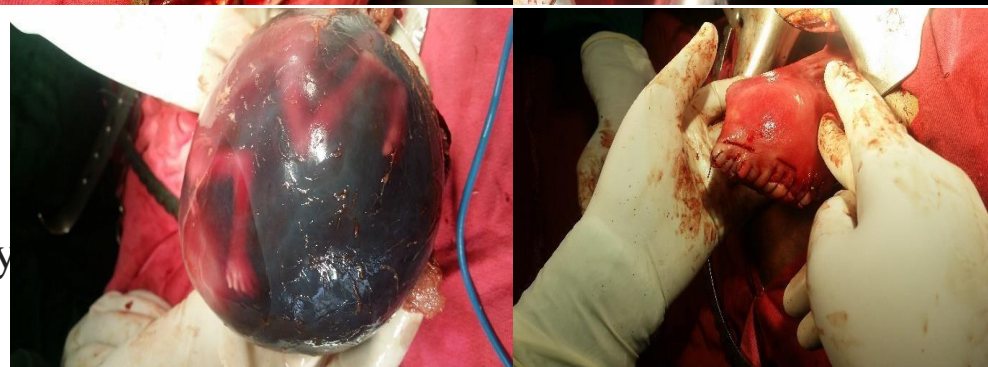
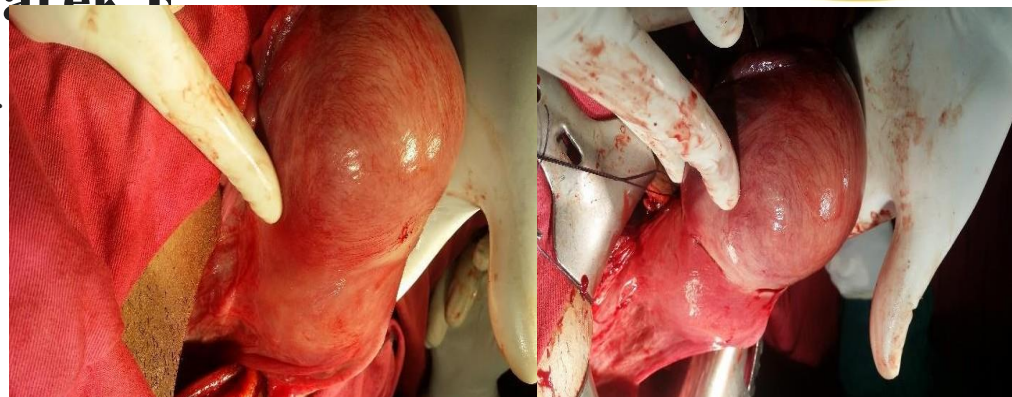
Case

A 25year old G II P I mother at GA of 17+4 weeks who was diagnosed with second trimester missed abortion.

She had mild lower abdominal pain with history of minimal vaginal spotting.

The cervix was closed with cervical motion tenderness with 16 week sized asymmetric uterus.

TV US - an empty uterus with 10 cm by 10 cm eccentrically located gestational sac with well-formed 15week pregnancy with negative heartbeat. No free fluid in the peritoneal cavity.



Conclusion

Cornual ectopic is a challenge in diagnosis and management. Although there are different conservative and less invasive surgical approaches, laparotomy still remains an integral part of surgical management of cornual pregnancy.